


Cortical myelination in toddlers and preschoolers with autism spectrum disorder

Bosi Chen^{1,2}  | Annika Linke¹ | Lindsay Olson^{1,2} | Jiwandeep Kohli^{1,2} |
Mikaela Kinnear¹ | Martin Sereno^{1,2} | Ralph-Axel Müller^{1,2,3} | Ruth Carper^{1,2,3} |
Inna Fishman^{1,2,3}

¹Brain Development Imaging Laboratories, Department of Psychology, San Diego State University, San Diego, California, USA

²SDSU/UC San Diego Joint Doctoral Program in Clinical Psychology, San Diego, California, USA

³Center for Autism and Developmental Disorders, San Diego State University, San Diego, California, USA

Correspondence

Bosi Chen and Inna Fishman, SDSU/UC San Diego Joint Doctoral Program in Clinical Psychology, San Diego, CA, USA.
Email: bchen2@sdsu.edu;
ifishman@sdsu.edu

Funding information

National Institute of Mental Health, Grant/Award Number: R01MH107802

Abstract

Intracortical myelin is thought to play a significant role in the development of neural circuits and functional networks, with consistent evidence of atypical network connectivity in children with autism spectrum disorder (ASD). However, little is known about the development of intracortical myelin in the first years of life in ASD, during the critical neurodevelopmental period when autism symptoms first emerge. Using T1-weighted (T1w) and T2w structural magnetic resonance imaging (MRI) in 21 young children with ASD and 16 typically developing (TD) children, ages 1.5–5.5 years, we demonstrate the feasibility of estimating intracortical myelin in vivo using the T1w/T2w ratio as a proxy. The resultant T1w/T2w maps were largely comparable with those reported in prior T1w/T2w studies in TD children and adults, and revealed no group differences between TD children and those with ASD. However, differential associations between T1w/T2w and age were identified in several early myelinated regions (e.g., visual, posterior cingulate, precuneus cortices) in the ASD and TD groups, with age-related increase in estimated myelin content across the toddler and preschool years detected in TD children, but not in children with ASD. The atypical age-related effects in intracortical myelin, suggesting a disrupted myelination in the first years of life in ASD, may be related to the aberrant brain network connectivity reported in young children with ASD in some of the same cortical regions and circuits.

KEYWORDS

autism spectrum disorder, brain maturation, early childhood, intracortical myelin, neurodevelopment, neuroimaging

1 | INTRODUCTION

Although symptoms of autism spectrum disorder (ASD) emerge early in postnatal life (Pierce et al., 2011) and can be reliably identified during the second year of life (Corsello

et al., 2013; Ozonoff et al., 2008, 2015; Pierce et al., 2019; Sacrey et al., 2018), most children with ASD are not diagnosed until they are 4–5 years old (Maenner et al., 2020), in large part due to the lack of clinically meaningful biomarkers. The implications of delayed identification are significant,

This is an open access article under the terms of the [Creative Commons Attribution-NonCommercial](https://creativecommons.org/licenses/by-nc/4.0/) License, which permits use, distribution and reproduction in any medium, provided the original work is properly cited and is not used for commercial purposes.

© 2022 The Authors. *Developmental Neurobiology* published by Wiley Periodicals LLC.

given the positive impact of early interventions on both behavior and the developing brain (Dawson et al., 2012; Estes et al., 2015; Landa, 2018). The current consensus on the underlying neurobiology is that ASD originates prenatally, affecting early building blocks of brain circuit development and function, such as protein synthesis and cellular metabolism, with cascading effects on neuronal proliferation and migration, synaptogenesis and synaptic signaling, myelination, and network formation (Courchesne et al., 2019; Gordon & Geschwind, 2020). However, the current understanding of these fundamental neurodevelopmental processes (e.g., synaptic pruning (Spear, 2013) or myelination (Abrahám et al., 2010; Chapman & Hill, 2020) is limited by the scarcity of brain imaging studies in young children with ASD (before 4–5 years of age). This is in part due to the known practical and methodological challenges of acquiring high-quality imaging data early in life (Turesky et al., 2021).

Although much of the developmental neurobiology of ASD remains unknown, a few consistent findings have emerged from the relatively limited but growing number of MRI studies in infants and toddlers at risk for, or with first symptoms of autism, including prospective studies of infant siblings of older children with ASD. The most consistently reported finding to date is enlargement of brain volume early in life (Courchesne et al., 2001; Hazlett et al., 2005, 2011; Nordahl et al., 2011). This early brain overgrowth appears to reflect accelerated growth rate particularly between 1 and 2 years of age (Hazlett et al., 2011), affecting both white and gray matter volumes (Hazlett et al., 2005), and being possibly driven by cortical surface area hyper-expansion between 6 and 12 months of age (Hazlett et al., 2017). Additionally, a number of cross-sectional and longitudinal diffusion-weighted imaging studies have reported increased structural connectivity (indexed by greater fractional anisotropy [FA]) across multiple white matter tracts (e.g., corpus callosum, cingulum, arcuate fasciculus) in infants and toddlers who either have been or are later diagnosed with ASD (Conti et al., 2017; Solso et al., 2016; Wolff et al., 2012; Xiao et al., 2014). The early increase in structural connectivity—contrasted with broadly reduced structural connectivity (i.e., lower FA) in older children and adults with ASD (Travers et al., 2012)—is thought to indicate an accelerated white matter growth in the first years of life in ASD, consistent with the aforementioned accelerated trajectory of volumetric growth.

While these findings provide indirect evidence of altered brain maturation early in life in ASD, our understanding of the specific neurodevelopmental processes contributing to atypical early growth and structural connectivity remains limited. Among such fundamental processes shaping the brain structure and function is myelination which is essential for efficient neural communication (Liu et al., 2019), as myelinated axons allow for rapid and reliable propagation of neuronal signals across the brain. Equally critical for brain maturation and connectivity is intracortical myelination found predomi-

nately in the deeper cortical layers (Fields, 2014), in part due to spread of the white matter myelin into the periphery of cortical neuropil (Shaw et al., 2008; Sowell et al., 2004). Intracortical myelination is essential for establishing and maintaining neural circuitry, as it contributes to fine-tuning the timing and synchrony of neural networks (Haroutunian et al., 2014). In typical development, the maturational timing of intracortical myelination, which commences at or near birth (Arnold & Trojanowski, 1996), follows a general primary-to-association cortices gradient (Sydnor et al., 2021), with unimodal primary sensory and motor cortices being highly myelinated by 1 year of age, and transmodal association areas in frontal and temporal cortices exhibiting more protracted myelination, continuing at least through the third decade of life (Deoni et al., 2015; Grydeland et al., 2019; Rowley et al., 2017; Shafee et al., 2015). Critically, this maturational principle parallels the development of brain network connectivity in healthy development (Chen, Linke, Olson, Ibarra, Kinnear, et al., 2021; Dong et al., 2021; Gao et al., 2015), with recent evidence suggesting that the timing of functional network maturation and differentiation may be disrupted in toddlers with ASD (Chen, Linke, Olson, Ibarra, Reynolds, et al., 2021).

Although no neuroimaging techniques allow direct measurement of myelin in the human brain *in vivo*, advanced MRI acquisition methods permit estimation of myelin content through either quantitative imaging, such as voxel-wise mapping of longitudinal or transverse relaxation times (Bock et al., 2013; Geyer et al., 2011), or semiquantitative ratio of T1-weighted (T1w) and T2w signal intensity (Glasser et al., 2013; Glasser & Van Essen, 2011). The T1w/T2w ratio has been shown to successfully map the regional differences in myelin content (Glasser & Van Essen, 2011) and has been incorporated in the multimodal minimal preprocessing pipelines for the Human Connectome Project (Glasser et al., 2013). Investigating the change in the T1w/T2w-estimated myelin content over much of the human life span in a large cross-sectional cohort of neurotypical children and adults between ages 8 and 83 years, Grydeland et al. (2013) reported linear increases in the T1w/T2w-estimated intracortical myelin content through the late 30s, followed by about 20 stable years and a gradual decline from the late 50s. The T1w/T2w ratio has also been associated with cognitive performance, especially on tasks of cognitive control (Grydeland et al., 2013; Grydeland et al., 2016). Thus, the T1w/T2w ratio may be a well-suited MRI-accessible proxy for investigating the development of intracortical myelin in young children with ASD, which, to our knowledge, has yet to be evaluated.

To enhance our understanding of early neurodevelopment in autism, the current study sets out to examine age-related effects in intracortical myelin in young children with ASD, compared to typically developing (TD) age-matched peers, using both T1w and T2w structural MRI data acquired during natural nocturnal sleep. Given the lack of previous

studies using the T1w/T2w ratio in young children with ASD, we expected to find main effects of diagnosis, but had no a priori hypotheses regarding the direction of potential effects.

2 | METHODS AND MATERIALS

2.1 | Participants

This study includes data from young children enrolled in the San Diego State University (SDSU) Toddler MRI Project, an ongoing longitudinal study of early brain markers of ASD. Children between the ages of 18 and 42 months with a diagnosis of ASD (or behavioral concerns consistent with ASD symptoms) were referred to the study from specialty autism clinics, state-funded early education and developmental evaluation programs, local pediatricians, service providers, and community clinics, and are being followed up through age 5 years. TD children were recruited from the community, including early head start programs, and via print and social media advertisements. Participants in either group were screened and excluded for any co-occurring neurological disorders (e.g., cerebral palsy), history of perinatal CNS infection or gross CNS injury, nonfebrile seizures, and contraindications for MRI. Participants with known syndromic forms of ASD (e.g., fragile X or Rett syndrome), as ascertained from parent report, were also excluded. To limit known risk factors for developmental delays among children enrolled in the TD group, TD participants were also screened and excluded for prematurity (<36 weeks of gestation), family history (in first-degree relatives) of ASD, intellectual disability, or other heritable psychiatric or neurological disorders. The research protocol was approved by the institutional review boards of SDSU and University of California San Diego, and the County of San Diego Health and Human Services Agency. Written informed consent was obtained from the caregivers.

This report includes cross-sectional data from 21 children with ASD and 16 TD participants, ages 1.5–5 years, for whom high-quality T1w and T2w anatomical MRI data acquired in the same session (during natural sleep; see Section 2.3 below for details) were available. While 32 children with ASD and 23 TD children had completed the full imaging protocol, data from 11 children with ASD and 7 TD children were excluded following stringent data quality assessment, as detailed below in Section 2.4. Participants with ASD and TD children were matched at the group level on age and gender distribution (see Table 1 for demographic characteristics of the sample).

2.2 | Diagnostic and developmental assessment

Upon enrollment, diagnoses of ASD (or clinical best estimate (Ozonoff et al., 2015) in children younger than age

3 years) were established at a specialty clinic (SDSU Center for Autism and Developmental Disorders) using standardized measures in combination with clinical judgment, in accordance with the current recommendations by the American Academy of Pediatrics and Society for Developmental and Behavioral Pediatrics (Weitzman & Wegner, 2015). Only participants who met diagnostic criteria for ASD, or clinical best estimate, on the DSM-5 (APA, 2013) were included in the ASD group. Because diagnostic evaluation is repeated at follow-up visits in the context of the larger longitudinal study, only data from children with confirmed diagnosis were included in the current dataset. The diagnoses were supported by the Autism Diagnostic Observation Schedule-Second Edition (Lord et al., 2012) administered by research-reliable clinicians, the Social Communication Questionnaire (Lord & Rutter, 2003), or the Autism Diagnostic Interview-Revised (Lord et al., 1994) administered to caregivers of children 36 months old and older, and expert clinical judgment (by two senior authors). Developmental skills were assessed in all TD and ASD participants with the Mullen Scales of Early Learning (Mullen, 1995), a clinician-administered standardized assessment of cognitive, language, and motor development. The Vineland Adaptive Behavior Scales, Second Edition, Survey Interview (Sparrow et al., 2005), a semistructured interview, was administered to caregivers to assess the child's adaptive development skills demonstrated at home and other settings; the Vineland scores were utilized to support the diagnostic and developmental classification, and are not used as variables of interest in the current analyses. The Social Communication Questionnaire (Lord & Rutter, 2003), a screener for ASD, was administered to caregivers of all participants, with no TD participants exceeding the clinical cut-off score of 15 (all TD scores ≤ 10 ; see Table 1).

2.3 | MRI data acquisition

MRI data were collected during natural nocturnal sleep on a 3T GE Discovery MR750 MRI scanner, using a Nova Medical 32-channel head coil. Whole-brain high-resolution anatomical images were obtained using a fast 3D spoiled gradient recalled (FSPGR) T1-weighted sequence (voxel size = 0.8mm^3 , NEX = 1, TE/TI = min full/1060 ms, flip angle = 8° , FOV = 25.6 cm, matrix = 320×320 , receiver bandwidth 31.25 HZ) and Cube T2-weighted sequence (voxel size = 0.8mm^3 , NEX = 1, TR = 3200 ms, TE = minimum, FOV = 25.6 cm, matrix = 320×320 , bandwidth 125htz). Motion during T1w and T2w scans was corrected in real-time using three navigator scans and prospective motion correction (White et al., 2010), and images were bias corrected using the GE PURE option. Other MRI data, including functional and diffusion MRI, were also acquired but are not included in this study.

TABLE 1 Participant characteristics and demographic information

	ASD (<i>n</i> = 21)	TD (<i>n</i> = 16)	ASD vs. TD	
	Mean ± SD (min–max)	Mean ± SD (min–max)	<i>t</i> / χ^2	<i>p</i> -value
Age at scan (months)*	42.7 ± 12.8 (21–62)	41.8 ± 15.4 (20–65)	<i>t</i> (35) = 0.19	.85
Gender (M/F)	16/5	9/7	χ^2 (1) = 1.65	.20
Ethnicity (Hispanic/Non-Hispanic) ^a	9/10	6/10	χ^2 (1) = 0.35	.56
Race (White/Black/More-than-one/Asian) ^b	16/0/3/1	13/2/0/0	–	–
Gestational age (weeks) ^c	39.1 ± 1.9 (35–43)	39.6 ± 1.2 (37–42)	<i>t</i> (34) = –1.09	.29
Birth weight (grams) ^d	3276.2 ± 583.1 (2098–4394)	3451.6 ± 363.0 (2863–4082)	<i>t</i> (33) = –1.04	.30
Delivery method (Vaginal/C-section)	13/8	13/3	χ^2 (1) = 1.63	.20
Maternal education level (%)				
High school or some college credit, but <1 year	38%	6%	–	–
Associate degree	10%	0	–	–
Bachelor's degree	10%	44%	–	–
Master's degree	29%	44%	–	–
Professional degree (MD, PhD, JD)	14%	6%	–	–
MSEL Early Learning Composite, Standard Score	75.3 ± 17.6 (49–105)	103.1 ± 16.1 (80–136)	<i>t</i> (35) = –4.95	<.001
SCQ Total Score ^e	14.3 ± 9.2 (3–35)	4.7 ± 2.4 (1–9)	<i>t</i> (33) = 4.02	<.001
ADOS-2 Calibrated Severity Score	5.9 ± 2.2 (2–9)	–	–	–
Total Brain Volume (cm ³)	1099.8 ± 99.5 (910.0–1282.7)	1052.5 ± 100.9 (813.9–1202.3)	<i>t</i> (35) = 1.42	.16
Gray/White CNR	2.0 ± 0.2 (1.7–2.5)	1.9 ± 0.1 (1.7–2.1)	<i>t</i> (35) = 1.50	.14

Abbreviations: ADOS-2, Autism Diagnostic Observation Schedule Second Edition; CNR, contrast-to-noise ratio; F, female; M, male; MSEL, Mullen Scales of Early Learning; SCQ, Social Communication Questionnaire.

*MRI data were acquired within 3 weeks of the diagnostic and behavioral evaluation.

^aEthnicity data are missing for two ASD subjects.

^bRace data are missing for one ASD and one TD subjects.

^cGestational age data are missing for one ASD subject.

^dBirth weight data are missing for two ASD subjects.

^eSCQ data are missing for two ASD subjects.

In preparation for the scan night, and to optimize MRI data acquisition, a comprehensive habituation protocol was implemented. An individualized scan night sleep strategy (e.g., time of arrival, approximating home-like sleeping arrangements, including access to a double MRI bed for co-sleeping families, rocking chair, modular playpen mounted on the MRI bed resembling a crib, lighting in the MRI suite) was developed for each child, based on the typical bedtime routines assessed in advance with an in-house Sleep Habits Questionnaire. To habituate the child to the scanning environment, the parents were instructed to practice nightly inserting soft foam child-size earplugs after the child had fallen asleep, and to play an mp3 file containing the MRI sounds of the scan sequences employed in the study at progressively louder volumes for a week. On the night of the scan, noise protection was achieved with MRI compatible headphones (MR Confon) and earplugs. Scanning commenced after approximately 30–50 min of sleep, with the T1w sequence acquired about 15 min into the scanning session and the T2w scan being the

last sequence acquired approximately 40 min after the start of scanning.

2.4 | MRI data preprocessing and quality assessment

All structural images were visually inspected for motion-related and other artifacts. Whole-brain average gray/white contrast-to-noise ratio (CNR) was calculated for each participant's T1w image (see Table 1). The Human Connectome Project minimal preprocessing structural pipelines (*PreFreeSurfer*, *FreeSurfer*, and *PostFreeSurfer*) were employed to perform cortical reconstruction and to generate cortical myelin maps (Glasser et al., 2013). Briefly, the *PreFreeSurfer* pipeline was used to correct for gradient nonlinearity distortion, to align the T1w and T2w images with a six degrees of freedom rigid body transformation, and to correct for intensity inhomogeneity, including correction for B1-bias and some

B1+bias in the T1w and T2 images by estimating the bias field F from the square root of the product of the T1w and T2w images after thresholding out nonbrain tissues.

The *FreeSurfer* pipeline used a modified FreeSurfer's (v.5.3.0-HCP) recon-all pipeline (Dale et al., 1999; Fischl, Sereno, & Dale, 1999; Fischl, Sereno, Tootell, et al., 1999) to perform brain extraction, automated tissue segmentation, surface topology correction, and white and pial surface generation on the distortion- and bias-corrected T1w images in native volume space derived from the *PreFreeSurfer* pipeline. The T2w to T1w registration was further improved using FreeSurfer's BBRegister (Greve & Fischl, 2009).

Surface myelin maps were generated with the *Post-FreeSurfer* pipeline, using the methods described in Glasser and Van Essen (2011) and Glasser et al. (2014). The T1w/T2w ratio images were obtained by dividing the T1w images by the aligned T2w images and were sampled at mid-thickness between the white and pial surfaces as a proxy of intracortical myelin. Residual bias field in the T1w/T2w images was corrected by modeling the expected low spatial frequency distribution of T1w/T2w intensities across the surface and subtracting it from the individual T1w/T2w-estimated myelin maps (Glasser & Van Essen, 2011; Glasser et al., 2014).

All T1w and T2w images and FreeSurfer outputs were examined slice-by-slice by two independent raters to assess overall image quality and identify any inaccuracies in surface placement. Of the 32 datasets from children with ASD and 23 datasets from TD children with both T1w and T2w images available, data from 10 ASD and seven TD children were excluded due to major artifacts in the T1w or T2w image, such as ghosting and ringing, and/or surface placement inaccuracies on the FreeSurfer output of the T1w image. All T1w/T2w-estimated myelin maps were also visually inspected, and whole brain mean T1w/T2w ratio was calculated for each participant. Data from one child with ASD with the whole brain mean T1w/T2w ratio greater than two standard deviations above the group mean was identified as an outlier and excluded from the analysis. The excluded children ($n = 18$) did not significantly differ from those included in the study with regard to their age ($p = .63$), sex distribution ($p = .73$), overall developmental skills ($p = .33$) or, among children with ASD, autism symptom severity ($p = .27$).

2.5 | Statistical analysis

2.5.1 | Regions of interest

The average T1w/T2w ratio values were extracted from 34 cortical regions of interest (ROIs) per hemisphere from the Desikan–Killiany atlas (Desikan et al., 2006). In order to

reduce the number of comparisons, we focused on the regions known to undergo rapid myelination in the first years of life (Deoni et al., 2015). Thus, only ROIs with the T1w/T2w ratio greater than the average whole-brain T1w/T2w for this cohort (T1w/T2w ratio >2.2) were selected for subsequent analyses, resulting in 11 ROIs. These highly myelinated cortical regions included pericalcarine, cuneus, lingual, isthmus cingulate, transverse temporal, lateral occipital, postcentral, posterior cingulate, paracentral, precentral, and precuneus cortices, encompassing the primary somatosensory, motor, visual, auditory, and posterior parts of the cingulate cortices. Given the similar rate of myelin development in the left and right hemisphere reported in a large cohort of 1- to 6-years old children (Deoni et al., 2015), we averaged between the left and right homologous ROIs to calculate the mean T1w/T2w ratio for each ROI.

2.5.2 | T1w/T2w ratio analyses

Linear regression models were used with T1w/T2w ratio as the outcome variable and diagnostic group, age, and age by group interaction as predictors, for each of the selected ROIs. Sex, gray/white CNR, and total brain volume (TBV) were included as covariates in all regression models during model specification state, and retained only if revealed to be significant predictors. Gray/white CNR did not differ between groups (see Table 1) nor accounted for significant variance ($ps > .2$) in any of the models; as a result, it was removed from the final models. Corrections for multiple comparisons were conducted using Benjamini–Hochberg False Discovery Rate (FDR) at $q < 0.1$. Follow-up partial correlations were calculated between age and T1w/T2w ratio for each group for those ROIs with significant age by group interactions, while controlling for covariates revealed to be significant predictors.

2.5.3 | Correlations with autism symptoms

Associations between estimated myelin content and autism symptoms (in children with ASD only) were examined with linear regression models with T1w/T2w ratio as the outcome variable, and ADOS-2 Calibrated Severity Scores (CSS, an index of ASD symptom severity, which allows comparisons across ages and language abilities) as predictor, controlling for age, sex, and MSEL Early Learning Composite (ELC, a standard score indexing child's overall developmental level). These models were only applied for the ROIs showing significant diagnostic group, or age by group interaction effects in the main analysis. Benjamini–Hochberg FDR at $q < 0.1$ was used to correct for multiple comparisons.

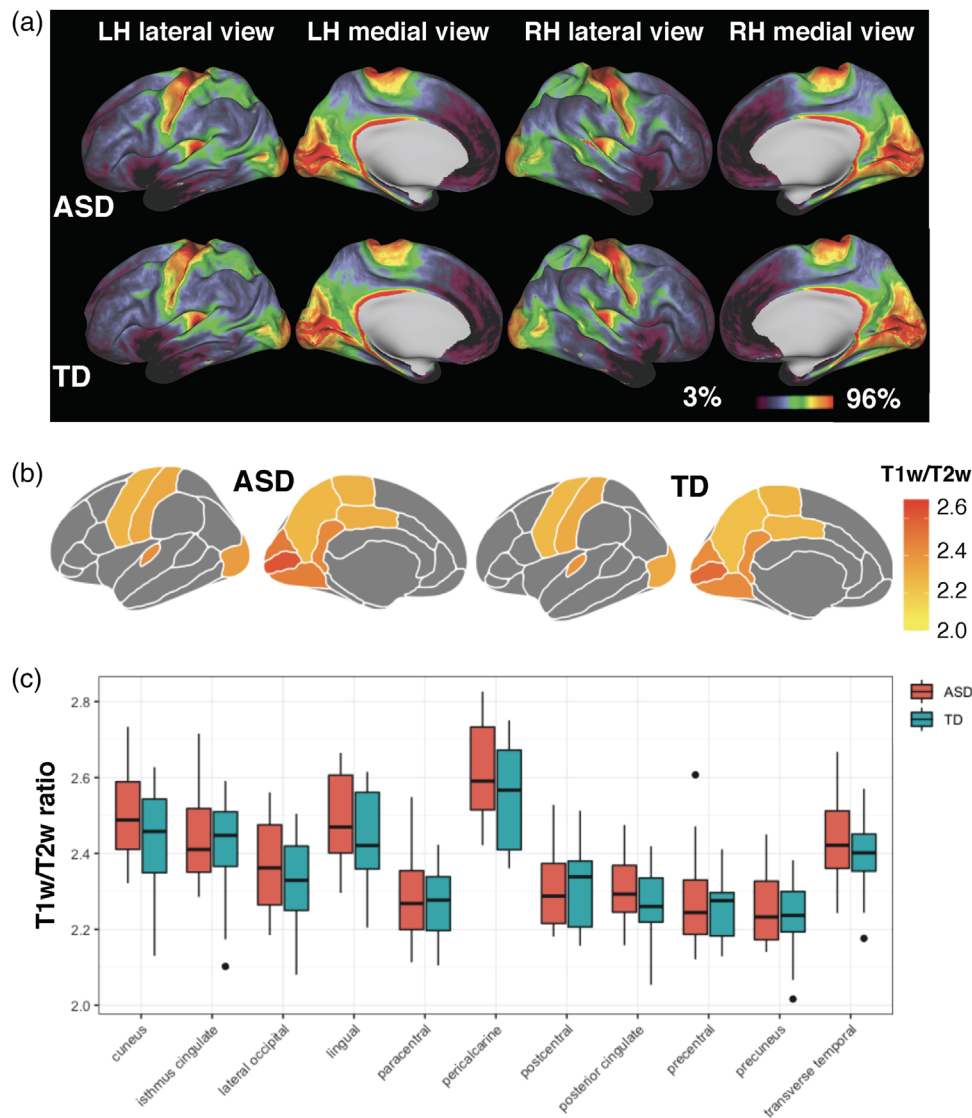


FIGURE 1 Estimated myelin content (T1-weighted [T1w]/T2w ratio) in young children with autism spectrum disorder (ASD) and typically developing (TD) children. (a) Average T1w/T2w ratio maps in the ASD and TD groups. Group average T1w/T2w ratio projected on the inflated surface. In all medial surface panels, the medial wall is masked. The color palette reflects T1w/T2w ratio percentile rank indexing lightly myelinated cortex in purple and more highly myelinated cortex in red. (b and c) Estimated myelin content (T1w/T2w ratio, averaged across hemispheres) for the 11 regions of interest (ROIs), in the ASD and TD groups. The 11 ROIs with the highest estimated myelin content (T1w/T2w ratio greater than the average whole-brain T1w/T2w ratio for the whole cohort) include pericalcarine, cuneus, lingual, isthmus cingulate, transverse temporal, lateral occipital, postcentral, posterior cingulate, paracentral, precentral, and precuneus cortices. Panel b shows average T1w/T2w ratio per group, and panel c shows distribution of the T1w/T2w values within each group, for each ROI

3 | RESULTS

The resultant T1w/T2w maps for the ASD and TD groups are shown in Figure 1a. Overall, the T1w/T2w spatial patterns and distribution were very similar for children in the ASD and TD groups, with the motor/somatosensory strip in the central sulcus, visual cortex in the occipital lobe, primary auditory areas in Heschl's gyrus, and posterior aspects of the cingulate cortex showing the highest T1w/T2w values. Regions with the lowest myelination included the temporal pole, medial prefrontal cortex, and the anterior cingulate cortex. These patterns are

highly consistent with those reported in adults (Glasser & Van Essen, 2011) and in typically developing young children in the same age range (obtained with a different myelin mapping method; Deoni et al., 2015).

3.1 | Group comparisons and age-related effects on T1w/T2w ratio

Results of the regression analyses revealed no significant group differences (ASD vs. TD) in the average T1w/T2w ratio

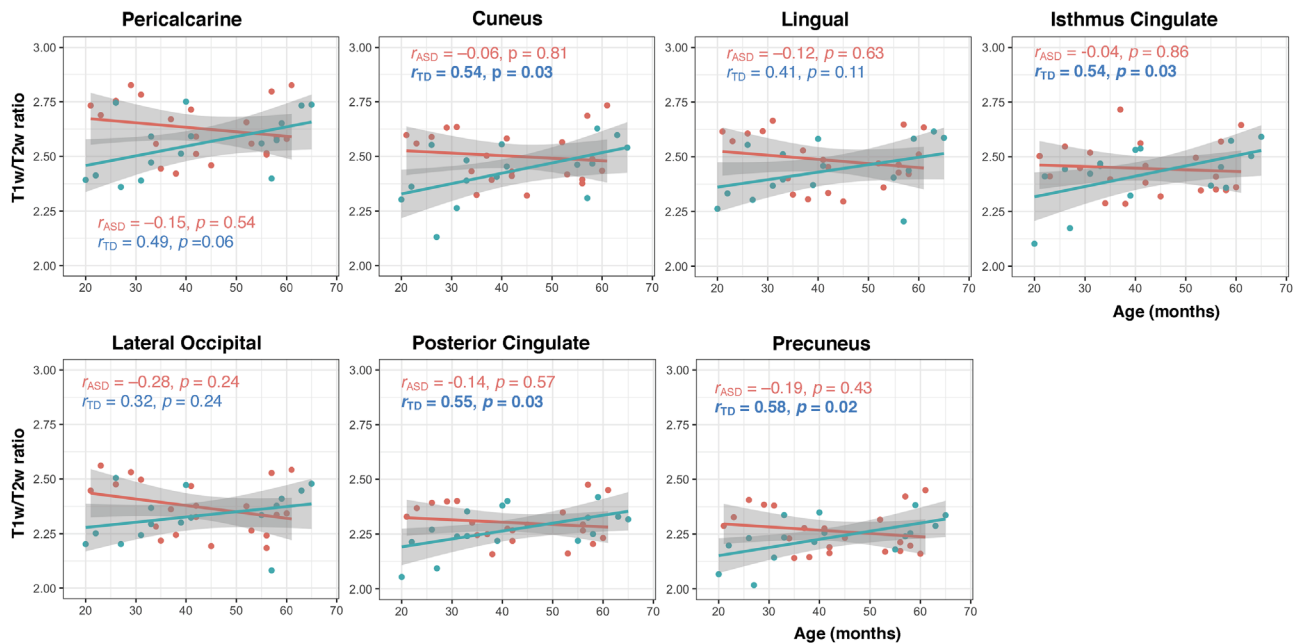


FIGURE 2 Correlations between estimated myelin content and age in the autism spectrum disorder (ASD) and typically developing (TD) groups. Scatterplots of correlations between T1w/T2w ratio and age, in seven out of 11 regions of interest (ROIs) where significant age by diagnostic group interaction effects were detected. r -Values denote bivariate (zero-order) correlation coefficients for the ASD and TD groups, with significant within-group correlations indicated in bold font. Bivariate correlations are presented because covariates (sex, contrast-to-noise ratio [CNR], and total brain volume [TBV]) did not account for significant variance in these models

in the selected 11 ROIs (Figure 1b,c). However, significant age by group interaction effects ($q < 0.1$) was identified in seven out of the 11 ROIs (including the pericalcarine, cuneus, lingual, isthmus cingulate, lateral occipital, posterior cingulate, and precuneus cortices), with a consistent pattern of positive associations between T1w/T2w and age in TD children (correlation coefficients $r = [0.32\text{--}0.58]$) and a general lack of such relationship with age in the ASD group (correlation coefficients $r = [-0.28\text{--}0.04]$; see scatterplots in Figure 2). Sex and TBV did not account for significant variance in these models.

3.2 | Links with autism symptoms

There were no significant associations between estimated myelin content (T1w/T2w ratio) and autism symptoms (ADOS-2 CSS) after controlling for age, sex, and overall developmental skills (Mullen ELC) in the seven ROIs identified in the main analyses.

3.3 | Post hoc examination of links between T1w/T2w ratio and other morphometric indices of cortical maturation

Given the rapid brain volume growth and prominent morphometric changes in the first years of life (Gilmore et al., 2012; Li

et al., 2013; Lyall et al., 2015), we conducted post hoc analyses to explore whether T1w/T2w ratio relates to gray matter volume in the cortical ROIs showing significant age by group interaction effects in the main analysis. Linear regression models with T1w/T2w ratio as the outcome variable, and diagnostic group, cortical volume, and group by volume interaction as predictors, while controlling for age, sex, and TBV were employed (cortical volumes were automatically calculated at each FreeSurfer surface vertex during preprocessing and were averaged across all vertices within each ROI). Corrections for multiple comparisons were conducted using Benjamini–Hochberg FDR at $q < 0.1$.

These analyses revealed significant group by volume interaction effects in the cuneus, isthmus cingulate, and precuneus cortices, after correcting for multiple comparisons ($q < 0.1$). Age, sex, and TBV did not account for significant variance in any of these models. Follow-up correlational analyses between T1w/T2w and ROI volume in each group revealed a significant positive association between T1w/T2w and volume in the cuneus in the TD group ($r = 0.74, p < .001$), indicating that the two indices of cortical maturation co-vary in young TD children, while such a relationship was not present in the ASD group (see Figure 3). Because cortical volume is, by and large, a product of cortical thickness and surface area, we conducted an additional exploratory analysis to examine whether the atypical relationship between cortical myelin and gray matter volume observed in the ASD group may be related to atypical cortical thinning or surface area expansion

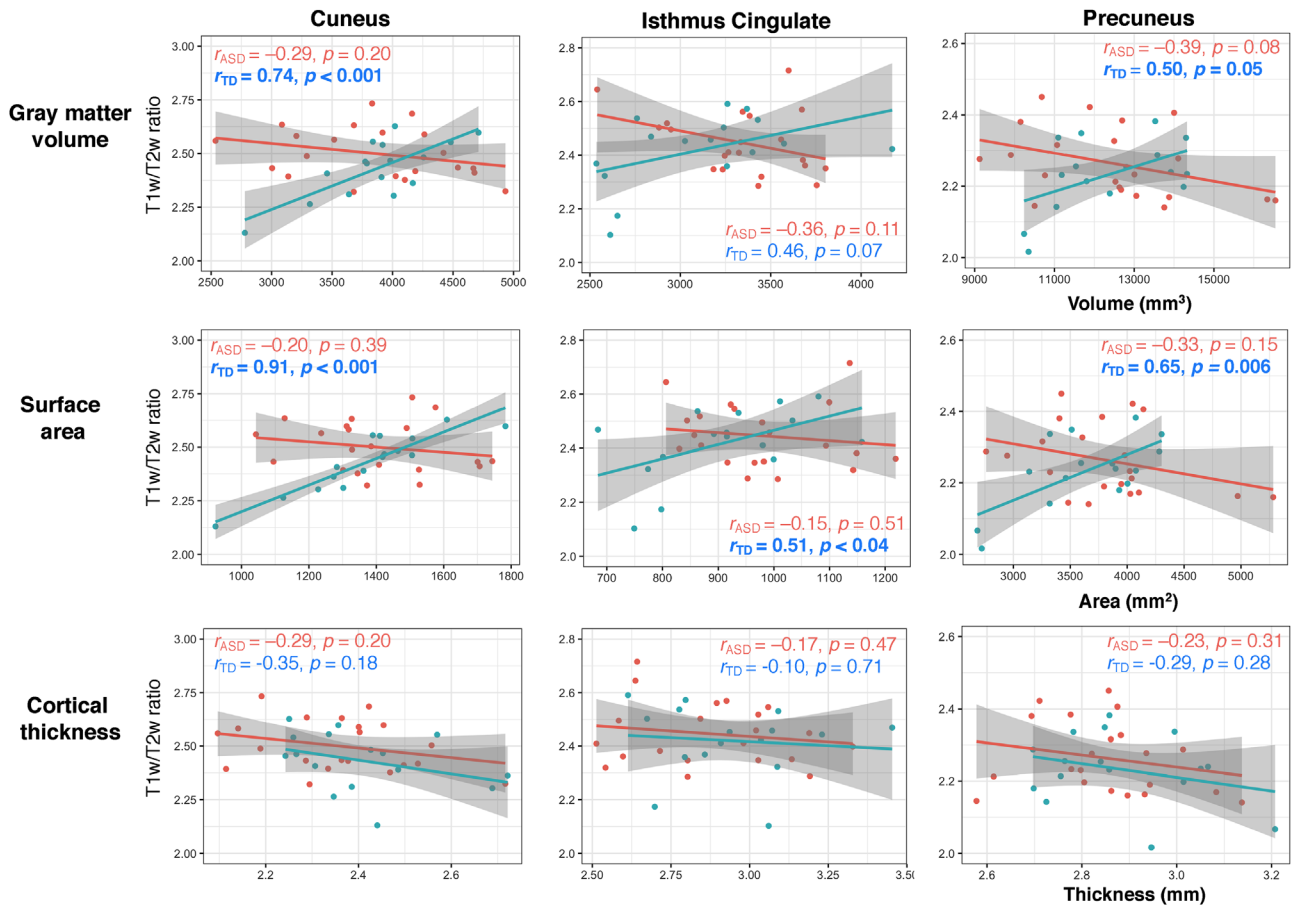


FIGURE 3 Correlations between estimated myelin content and morphometric indices of brain maturation. Scatterplots of correlations between T1w/T2w ratio and gray matter volume (top panel), surface area (middle panel), and cortical thickness (bottom panel) in three out of seven regions of interest (ROIs) where significant T1w/T2w by volume by diagnostic group interaction effects were detected (cuneus, isthmus cingulate, and precuneus cortices). r -Values denote correlation coefficients for the ASD and TD groups, with significant within-group correlations indicated in bold font

(thought to have different genetic origins and distinct developmental trajectories; Wierenga et al., 2014). Follow-up correlational analyses between T1w/T2w and surface area/cortical thickness conducted for the three ROIs (cuneus, isthmus cingulate, and precuneus) revealed no significant relationships between T1w/T2w ratio and cortical thickness, in either the ASD or TD groups. However, positive associations between T1w/T2w and surface area were identified in all three ROIs in the TD but not in the ASD group, mirroring the relationship between T1w/T2w and cortical volume in the same ROIs (Figure 3).

4 | DISCUSSION

To our knowledge, this is the first study to examine intracortical myelin in toddlers and preschoolers with ASD. Our primary aim was to test the feasibility of using the T1w/T2w ratio as an estimate of intracortical myelin content in young children with ASD, and to examine the age-related effects on

T1w/T2w across early childhood in ASD (cross-sectionally), compared to typical development. We also set out to explore whether, in children with ASD, estimated intracortical myelin content in the rapidly myelinated regions was associated with autism symptoms, and whether it was related to other indices of cortical maturation. Results revealed that the overall spatial patterns of intracortical myelin distribution estimated with T1w/T2w in young children with ASD were largely comparable to the patterns observed in the TD group, as well as to those reported in prior studies in TD children (Deoni et al., 2015) and adults (Glasser & Van Essen, 2011). Although direct between-group comparisons revealed no group differences in T1w/T2w between TD children and those with ASD, differential associations with age in the early myelinated areas, including visual, posterior cingulate, and precuneus cortices, were observed in the ASD and TD groups. Specifically, a consistent pattern of positive associations between intracortical myelin in these regions and age was detected in the TD group (cross-sectionally), indicating an age-related increase in estimated myelin content across the toddler and

preschool years. In contrast, such age-related effects were generally absent in the ASD group. Furthermore, differential relationships between intracortical myelin and cortical volumes and surface area in posterior cortices were detected in the ASD and TD groups, with estimated myelin content positively associated with volume and surface area in TD children, whereas such relationship was not present in young children with ASD. Finally, no significant association between cortical myelin and symptoms of autism was detected among children with ASD.

Our finding of aberrant age-related trajectories of estimated intracortical myelin content in young children with ASD, relative to TD children, suggests that this fundamental neurodevelopmental process is altered in the first years of life in autism. Although no diagnostic group differences (ASD vs. TD) in intracortical myelin content were detected, significant group by age interaction effects observed across several posterior cortical regions indicate that the developmental timing of myelination may be disordered in young children with ASD, in comparison to TD children who showed expected age-related increase in intracortical myelination. Across the human lifespan, intracortical myelination follows an inverted U-shape trajectory with an initial increase in intracortical myelin across most of the cortex continuing through at least the middle of the third decade of life, with the first wave of maturation in primary sensory and motor cortices followed by a second wave of maturation in association, limbic, and insular cortices (Grydeland et al., 2019, 2013; Rowley et al., 2017; Shafee et al., 2015). Based on our findings, albeit in a relatively modest size sample, this trajectory appears to be mis-timed (as assessed with cross-sectional design) in early childhood in ASD.

Although T1w/T2w had not been previously investigated in young children with ASD, a recent report (Darki et al., 2021) described lower T1w/T2w values in 5-month-old infants at familial risk for ASD in both white and gray matter in broadly distributed brain regions, compared to infants with no familial risk. Notably, some of the gray matter regions where significant group differences in T1w/T2w were observed in infants at risk for ASD overlap with the ROIs with significant group by age interaction effects in our cohort, including the cingulate, precuneus, and lateral occipital cortices. However, considerable methodological differences between the two studies preclude any further inferences (e.g., a volume-based approach for tissue segmentation, which limits the accuracy of delineation of gray and white matter, and voxel-wise calculation of T1w/T2w across the cortex, limiting the specification of the underlying neurobiological processes, used by Darki et al., vs. a surface-based approach for tissue segmentation and estimation of T1w/T2w at mid-thickness between the white and pial surfaces used in the current study). Additionally, it is unclear if these findings are specific to children with ASD given the lack of subsequent diagnostic confirmation for infants

at familial risk. Nonetheless, considered together with these results, our findings highlight the developmental significance of the T1w/T2w ratio as an index of aberrant neurodevelopment characterizing young children with, or at risk for ASD.

Notably, studies using other methodologically related MRI metrics (also dependent on image intensity variations and contrast, similarly to T1w/T2w) in ASD have shown blurring of the boundary between cerebral gray and white matter, where intracortical myelin is predominately found. Andrews and colleagues (2017) first reported reduced gray-white matter boundary contrast (GWC) in adults with ASD, consistent with earlier postmortem histological findings (Avino & Hutslers, 2010). The reduced GWC values in adults with ASD were driven primarily by increased gray matter intensity (GMI) across the cortical layers at different depths into the cortical sheet. This is pertinent because increased GMI may be driven by atypical myelination (Sowell et al., 2004) and/or differences in cytoarchitectural organization (Casanova et al., 2002). A subsequent study investigating age-related changes of GWC in youth and young adults with ASD (ages 7–25 years) found that the most prominent changes in GWC occur during childhood (Mann et al., 2018), suggesting that the disrupted GWC in ASD may not be exclusively driven by atypical gray matter cytoarchitecture (which is largely set around birth) but rather reflects ongoing, age-dependent changes in myelination. Finally, a recent longitudinal study in toddlers with familial risk of ASD reported that atypically increased GWC in the second year of life (in the context of the normative increase observed at this age in typical development) was associated with ASD diagnosis and symptom severity at age 3 years (Godel et al., 2021). Overall, although the GWC index is not specific to myelin content, its methodological interdependence with estimated myelin content (through similar reliance on image intensity variations and contrast in estimating the gray-white cortical boundary, where intracortical myelin is predominately found) makes these findings relevant to the pattern of results observed in young children with ASD in our study.

Broadly, the early disruption in intracortical myelination is significant in the context of its effects on the development of brain circuits and functional networks, including the inhibitory effects of myelin on axon sprouting and synapse formation and dendritic plasticity (McGee et al., 2005; Tomassy et al., 2014) thought to help stabilize the architecture of developing neural networks. The cortical regions where atypical age-related effects in intracortical myelin were observed in our cohort encompassed visual cortices (i.e., pericalcarine, cuneus, lingual, lateral occipital) and posterior nodes of the Default Mode Network (DMN; Buckner et al., 2008; Raichle et al., 2001) (i.e., isthmus cingulate, posterior cingulate, precuneus), with consistent reports of atypical functional connectivity in those circuits in ASD (Assaf et al., 2010; Keehn et al., 2013; Wang et al., 2021;

Yerys et al., 2015). The aberrant brain connectivity and network organization involving visual and DMN networks have been reported in young children with (or at risk for) ASD in particular, with atypical connectivity linked to autism symptoms or early behavioral signs of ASD (e.g., joint attention or core autism symptoms; Chen, Linke, Olson, Ibarra, Reynolds, et al., 2021; Eggebrecht et al., 2017; McKinnon et al., 2019).

Further, the atypical relationships between T1w/T2w ratio and gray matter volume/surface area in young children with ASD, compared to TD children, revealed in the post hoc analyses, suggest that the early disruption in intracortical myelination may be one of several aberrant cortical maturational processes underlying the atypical neurodevelopment in the first years of life in ASD. Namely, we found that, in posterior midline cortices, including posterior cingulate, precuneus, and cuneus, estimated intracortical myelin content and cortical volumes/surface area are robustly linked within individuals in TD children, suggesting effectively concomitant maturation of these indices of neurodevelopment. However, intracortical myelin and cortical volumes/surface area were not associated in children with ASD, indicating that the two may be uncoupled in early development in autism. As briefly discussed in Section 1, early accelerated growth in gray matter volume, possibly driven by surface area hyper-expansion, has been consistently reported in young children with ASD (Hazlett et al., 2017). Our findings expand on this literature by highlighting an additional aspect of atypical cortical development in autism, intracortical myelination, that can inform our understanding of the neurobiology of the ASD.

4.1 | Limitations and perspectives

While this study reports the first in vivo description of intracortical myelination in young children with ASD, some methodological limitations need to be acknowledged. The primary limitation is that the T1w/T2w ratio is not a direct measure of intracortical myelin content but rather a proxy that has been shown to successfully map the myeloarchitectonic properties in adults and typically developing children. Other factors can also contribute to the T1w/T2w measure such as iron content, which affects MRI signal contrast (Fukunaga et al., 2010), head motion affecting image quality which can indirectly affect the accurate placement of the cortical surface, as well as maturation of the local white matter (e.g., Giedd, 2004). Given the rigorous quality assurance of all structural images and exclusion of scans with major motion artifacts or surface placement inaccuracies, and the use of gray/white CNR as a measure of the overall image quality (which did not account for significant variance in any of the analyses), head motion is unlikely to be a major contributor for the current results. Additionally, although HCP pre-

processing pipeline includes an ad hoc correction method to minimize the residual B1+ bias in the T1w/T2w maps, this method works well for localizing cortical areas in individual scans, but may potentially attenuate individual differences and reduce sensitivity for detecting cross-participant differences (Ganzetti et al., 2014). An improved method for B1+ transmit field correction on the T1w/T2w-estimated myelin maps may be needed in future studies utilizing the T1w/T2w ratio measure. Other limitations include the relatively modest sample size limiting our study to an exploratory purpose only and the use of cross-sectional data to explore age-related effects. Future studies with larger samples and longitudinal data are necessary to map the developmental trajectories of intracortical myelination in the first years of life in ASD.

Critically, while the current study design does not allow inferences about whether the observed atypical maturational trajectories of intracortical myelin in young children with ASD reflect causation (i.e., pertain to the underlying etiology) or compensatory effects, these findings are nonetheless crucial for translational efforts given the recent evidence of adaptive myelination, modifiable by environmental experience (Fields, 2015; Forbes & Gallo, 2017). Specifically, the prolonged plasticity of intracortical myelin, especially in transmodal association cortices, provides an extended window of opportunity for modifications, through early interventions or other critical changes in an individual's socioemotional, educational, and other environmental experiences, to promote experience-dependent plasticity early in life in children with ASD (e.g., Rosen et al., 2019).

ACKNOWLEDGMENTS

This research was supported by the National Institutes of Health (R01MH107802 to IF). The funding sources had no role in study design, writing of the report, or the decision to submit the article for publication. The authors are grateful to Chris Fong, M.A. and Lisa Mash, Ph.D., of San Diego State University, and Tiffany Wang, M.S., of University of California, San Diego, for invaluable assistance with data collection. The authors' strongest gratitude goes to the children and families who so generously dedicated their time and effort to this research.

CONFLICT OF INTEREST

The authors declare no conflict of interest.

DATA AVAILABILITY STATEMENT

All behavioral and imaging data from this study will be shared through the National Institute of Mental Health Data Archive (NDA), Study Collection #2338.

ORCID

Bosi Chen  <https://orcid.org/0000-0002-0117-9757>

REFERENCES

- Abrahám, H., Vincze, A., Jewgenow, I., Veszprémi, B., Kravják, A., Gömöri, E., & Seress, L. (2010). Myelination in the human hippocampal formation from midgestation to adulthood. *International Journal of Developmental Neuroscience*, 28(5), 401–410. <https://doi.org/10.1016/j.ijdevneu.2010.03.004>
- Andrews, D. S., Avino, T. A., Gudbrandsen, M., Daly, E., Marquand, A., Murphy, C. M., Lai, M. C., Lombardo, M. V., Ruigrok, A. N., Williams, S. C., Bullmore, E. T., The Mrc Aims Consortium, Suckling, J., Baron-Cohen, S., Craig, M. C., Murphy, D. G., & Ecker, C. (2017). In vivo evidence of reduced integrity of the gray-white matter boundary in autism spectrum disorder. *Cerebral Cortex*, 27(2), 877–887. <https://doi.org/10.1093/cercor/bhw404>
- APA. (2013). *Diagnostic and Statistical Manual of Mental Disorders (DSM-5)*. American Psychiatric Association.
- Arnold, S. E., & Trojanowski, J. Q. (1996). Human fetal hippocampal development: I. Cytoarchitecture, myeloarchitecture, and neuronal morphologic features. *Journal of Comparative Neurology*, 367(2), 274–292. [https://doi.org/10.1002/\(SICI\)1096-9861\(19960401\)367:2<274::AID-CNE9>3.0.CO;2-2](https://doi.org/10.1002/(SICI)1096-9861(19960401)367:2<274::AID-CNE9>3.0.CO;2-2)
- Assaf, M., Jagannathan, K., Calhoun, V. D., Miller, L., Stevens, M. C., Sahl, R., O'Boyle, J. G., Schultz, R. T., & Pearlson, G. D. (2010). Abnormal functional connectivity of default mode sub-networks in autism spectrum disorder patients. *Neuroimage*, 53(1), 247–256. <https://doi.org/10.1016/j.neuroimage.2010.05.067>
- Avino, T. A., & Hutsler, J. J. (2010). Abnormal cell patterning at the cortical gray-white matter boundary in autism spectrum disorders. *Brain Research*, 1360, 138–146. <https://doi.org/10.1016/j.brainres.2010.08.091>
- Bock, N. A., Hashim, E., Janik, R., Konyer, N. B., Weiss, M., Stanisz, G. J., Turner, R., & Geyer, S. (2013). Optimizing T1-weighted imaging of cortical myelin content at 3.0 T. *Neuroimage*, 65, 1–12. <https://doi.org/10.1016/j.neuroimage.2012.09.051>
- Buckner, R. L., Andrews-Hanna, J. R., & Schacter, D. L. (2008). The brain's default network: Anatomy, function, and relevance to disease. *Annals of the New York Academy of Sciences*, 1124, 1–38. <https://doi.org/10.1196/annals.1440.011>
- Casanova, M. F., Buxhoeveden, D. P., Switala, A. E., & Roy, E. (2002). Neuronal density and architecture (Gray Level Index) in the brains of autistic patients. *Journal of Child Neurology*, 17(7), 515–521. <https://doi.org/10.1177/088307380201700708>
- Chapman, T. W., & Hill, R. A. (2020). Myelin plasticity in adulthood and aging. *Neuroscience Letters*, 715, 134645. <https://doi.org/10.1016/j.neulet.2019.134645>
- Chen, B., Linke, A., Olson, L., Ibarra, C., Kinnear, M., & Fishman, I. (2021). Resting state functional networks in 1-to-3-year-old typically developing children. *Developmental Cognitive Neuroscience*, 51, 100991. <https://doi.org/10.1016/j.dcn.2021.100991>
- Chen, B., Linke, A., Olson, L., Ibarra, C., Reynolds, S., Müller, R. A., Kinnear, M., & Fishman, I. (2021). Greater functional connectivity between sensory networks is related to symptom severity in toddlers with autism spectrum disorder. *Journal of Child Psychology and Psychiatry*, 62(2), 160–170. <https://doi.org/10.1111/jcpp.13268>
- Conti, E., Mitra, J., Calderoni, S., Pannek, K., Shen, K. K., Pagnozzi, A., Rose, S., Mazzotti, S., Scelfo, D., Tosetti, M., Muratori, F., & Cioni Guzzetta, G., (2017). Network over-connectivity differentiates autism spectrum disorder from other developmental disorders in toddlers: A diffusion MRI study. *Human Brain Mapping*, 38(5), 2333–2344. <https://doi.org/10.1002/hbm.23520>
- Corsello, C. M., Akshoomoff, N., & Stahmer, A. C. (2013). Diagnosis of autism spectrum disorders in 2-year-olds: A study of community practice. *Journal of Child Psychology and Psychiatry and Allied Disciplines*, 54(2), 178–185. <https://doi.org/10.1111/j.1469-7610.2012.02607.x>
- Courchesne, E., Karns, C. M., Davis, H. R., Ziccardi, R., Carper, R. A., Tigue, Z. D., Chisum, H. J., Moses, P., Pierce, K., Lord, C., Lincoln, A. J., Pizzo, S., Schreibman, L., Haas, R. H., Akshoomoff, N. A., & Courchesne, R. Y. (2001). Unusual brain growth patterns in early life in patients with autistic disorder: An MRI study. *Neurology*, 57(2), 245–254.
- Courchesne, E., Pramparo, T., Gazestani, V. H., Lombardo, M. V., Pierce, K., & Lewis, N. E. (2019). The ASD living biology: From cell proliferation to clinical phenotype. *Molecular Psychiatry*, 24(1), 88–107. <https://doi.org/10.1038/s41380-018-0056-y>
- Dale, A. M., Fischl, B., & Sereno, M. I. (1999). Cortical surface-based analysis. I. Segmentation and surface reconstruction. *Neuroimage*, 9(2), 179–194. <https://doi.org/10.1006/nimg.1998.0395>
- Darki, F., Nyström, P., McAlonan, G., Bölte, S., & Falck-Ytter, T. (2021). T1-weighted/T2-weighted ratio mapping at 5 months captures individual differences in behavioral development and differentiates infants at familial risk for autism from controls. *Cerebral Cortex*, 31(9), 4068–4077. <https://doi.org/10.1093/cercor/bhab069>
- Dawson, G., Jones, E. J., Merkle, K., Venema, K., Lowy, R., Faja, S., Kamara, D., Murias, M., Greenson, J., Winter, J., Smith, M., Rogers, S. J., & Webb, S. J. (2012). Early behavioral intervention is associated with normalized brain activity in young children with autism. *Journal of the American Academy of Child and Adolescent Psychiatry*, 51(11), 1150–1159. <https://doi.org/10.1016/j.jaac.2012.08.018>
- Deoni, S. C., Dean, D. C., 3rd, Remer, J., Dirks, H., & O'Muircheartaigh, J. (2015). Cortical maturation and myelination in healthy toddlers and young children. *Neuroimage*, 115, 147–161. <https://doi.org/10.1016/j.neuroimage.2015.04.058>
- Desikan, R. S., Ségonne, F., Fischl, B., Quinn, B. T., Dickerson, B. C., Blacker, D., Buckner, R. L., Dale, A. M., Maguire, R., Hyman, B. T., Albert, M. S., & Killiany, R. J. (2006). An automated labeling system for subdividing the human cerebral cortex on MRI scans into gyral based regions of interest. *Neuroimage*, 31(3), 968–980. <https://doi.org/10.1016/j.neuroimage.2006.01.021>
- Dong, H. M., Margulies, D. S., Zuo, X. N., & Holmes, A. J. (2021). Shifting gradients of macroscale cortical organization mark the transition from childhood to adolescence. *Proceedings of the National Academy of Sciences*, 118(28), e202444811. <https://doi.org/10.1073/pnas.2024448118>
- Engelbrecht, A. T., Elison, J. T., Feczko, E., Todorov, A., Wolff, J. J., Kandala, S., Adams, C. M., Snyder, A. Z., Lewis, J. D., Estes, A. M., Zwaigenbaum, L., Botteron, K. N., McKinstry, R. C., Constantino, J. N., Evans, A., Hazlett, H. C., Dager, S., Paterson, S. J., Schultz, R. T., ... Pruett, J. R., Jr. (2017). Joint attention and brain functional connectivity in infants and toddlers. *Cerebral Cortex*, 27(3), 1709–1720. <https://doi.org/10.1093/cercor/bhw403>
- Estes, A., Munson, J., Rogers, S. J., Greenson, J., Winter, J., & Dawson, G. (2015). Long-term outcomes of early intervention in 6-year-old children with autism spectrum disorder. *Journal of the American Academy of Child and Adolescent Psychiatry*, 54(7), 580–587. <https://doi.org/10.1016/j.jaac.2015.04.005>
- Fields, R. D. (2014). Myelin—More than insulation. *Science*, 344(6181), 264–266. <https://doi.org/10.1126/science.1253851>

- Fields, R. D. (2015). A new mechanism of nervous system plasticity: Activity-dependent myelination. *Nature Reviews Neuroscience*, *16*(12), 756–767. <https://doi.org/10.1038/nrn4023>
- Fischl, B., Sereno, M. I., & Dale, A. M. (1999). Cortical surface-based analysis. II: Inflation, flattening, and a surface-based coordinate system. *Neuroimage*, *9*(2), 195–207. <https://doi.org/10.1006/nimg.1998.0396>
- Fischl, B., Sereno, M. I., Tootell, R. B., & Dale, A. M. (1999). High-resolution intersubject averaging and a coordinate system for the cortical surface. *Human Brain Mapping*, *8*(4), 272–284. [https://doi.org/10.1002/\(sici\)1097-0193\(1999\)8:4<272::aid-hbm10>3.0.co;2-4](https://doi.org/10.1002/(sici)1097-0193(1999)8:4<272::aid-hbm10>3.0.co;2-4)
- Forbes, T. A., & Gallo, V. (2017). All wrapped up: Environmental effects on myelination. *Trends in Neuroscience*, *40*(9), 572–587. <https://doi.org/10.1016/j.tins.2017.06.009>
- Fukunaga, M., Li, T. Q., van Gelderen, P., de Zwart, J. A., Shmueli, K., Yao, B., Lee, J., Maric, D., Aronova, M. A., Zhang, G., Leapman, R. D., Schenck, J. F., Merkle, H., & Duyn, J. H. (2010). Layer-specific variation of iron content in cerebral cortex as a source of MRI contrast. *Proceedings of the National Academy of Sciences of the United States of America*, *107*(8), 3834–3839. <https://doi.org/10.1073/pnas.0911177107>
- Ganzetti, M., Wenderoth, N., & Mantini, D. (2014). Whole brain myelin mapping using T1- and T2-weighted MR imaging data. *Frontiers in Human Neuroscience*, *8*, 671. <https://doi.org/10.3389/fnhum.2014.00671>
- Gao, W., Alcauter, S., Elton, A., Hernandez-Castillo, C. R., Smith, J. K., Ramirez, J., & Lin, W. (2015). Functional network development during the first year: Relative sequence and socioeconomic correlations. *Cerebral Cortex*, *25*(9), 2919–2928. <https://doi.org/10.1093/cercor/bhu088>
- Geyer, S., Weiss, M., Reimann, K., Lohmann, G., & Turner, R. (2011). Microstructural Parcellation of the human cerebral cortex—From Brodmann’s post-mortem map to in vivo mapping with high-field Magnetic Resonance Imaging. *Frontiers in Human Neuroscience*, *5*, 19. <https://doi.org/10.3389/fnhum.2011.00019>
- Giedd, J. N. (2004). Structural magnetic resonance imaging of the adolescent brain. *Annals of the New York Academy of Sciences*, *1021*, 77–85. <https://doi.org/10.1196/annals.1308.009>
- Gilmore, J. H., Shi, F., Woolson, S. L., Knickmeyer, R. C., Short, S. J., Lin, W., Zhu, H., Hamer, R. M., Styner, M., & Shen, D. (2012). Longitudinal development of cortical and subcortical gray matter from birth to 2 years. *Cerebral Cortex*, *22*(11), 2478–2485. <https://doi.org/10.1093/cercor/bhr327>
- Glasser, M. F., Goyal, M. S., Preuss, T. M., Raichle, M. E., & Van Essen, D. C. (2014). Trends and properties of human cerebral cortex: Correlations with cortical myelin content. *Neuroimage*, *2*, 165–175. <https://doi.org/10.1016/j.neuroimage.2013.03.060>
- Glasser, M. F., Sotiropoulos, S. N., Wilson, J. A., Coalson, T. S., Fischl, B., Andersson, J. L., Xu, J., Jbabdi, S., Webster, M., Polimeni, J. R., Van Essen, D. C., Jenkinson, M., & Jenkinson, M. (2013). The minimal preprocessing pipelines for the Human Connectome Project. *Neuroimage*, *80*, 105–124. <https://doi.org/10.1016/j.neuroimage.2013.04.127>
- Glasser, M. F., & Van Essen, D. C. (2011). Mapping human cortical areas in vivo based on myelin content as revealed by T1- and T2-weighted MRI. *Journal of Neuroscience*, *31*(32), 11597–11616. <https://doi.org/10.1523/jneurosci.2180-11.2011>
- Godel, M., Andrews, D. S., Amaral, D. G., Ozonoff, S., Young, G. S., Lee, J. K., Nordahl, C. W., & Schaer, M. (2021). Altered gray-white matter boundary contrast in toddlers at risk for autism relates to later diagnosis of autism spectrum disorder. *Frontiers in Neuroscience*, *15*, 669194. <https://doi.org/10.3389/fnins.2021.669194>
- Gordon, A., & Geschwind, D. H. (2020). Human in vitro models for understanding mechanisms of autism spectrum disorder. *Molecular Autism*, *11*(1), 26. <https://doi.org/10.1186/s13229-020-00332-7>
- Greve, D. N., & Fischl, B. (2009). Accurate and robust brain image alignment using boundary-based registration. *Neuroimage*, *48*(1), 63–72.
- Grydeland, H., Vértes, P. E., Váša, F., Romero-Garcia, R., Whitaker, K., Alexander-Bloch, A. F., Bjørnerud, A., Patel, A. X., Sederevičius, D., Tamnes, C. K., Westlye, L. T., White, S. R., Walhovd, K. B., Fjell, A. M., & Bullmore, E. T. (2019). Waves of maturation and senescence in micro-structural MRI markers of human cortical myelination over the lifespan. *Cerebral Cortex*, *29*(3), 1369–1381. <https://doi.org/10.1093/cercor/bhy330>
- Grydeland, H., Walhovd, K. B., Tamnes, C. K., Westlye, L. T., & Fjell, A. M. (2013). Intracortical myelin links with performance variability across the human lifespan: Results from T1- and T2-weighted MRI myelin mapping and diffusion tensor imaging. *Journal of Neuroscience*, *33*(47), 18618–18630. <https://doi.org/10.1523/jneurosci.2811-13.2013>
- Grydeland, H., Westlye, L. T., Walhovd, K. B., & Fjell, A. M. (2016). Intracortical posterior cingulate myelin content relates to error processing: Results from T1- and T2-weighted MRI myelin mapping and electrophysiology in healthy adults. *Cerebral Cortex*, *26*(6), 2402–2410. <https://doi.org/10.1093/cercor/bhv065>
- Haroutunian, V., Katsel, P., Roussos, P., Davis, K. L., Altshuler, L. L., & Bartzokis, G. (2014). Myelination, oligodendrocytes, and serious mental illness. *Glia*, *62*(11), 1856–1877. <https://doi.org/10.1002/glia.22716>
- Hazlett, H. C., Gu, H., Munsell, B. C., Kim, S. H., Styner, M., Wolff, J. J., Elison, J. T., Swanson, M. R., Zhu, H., Botteron, K. N., Collins, D. L., Constantino, J. N., Dager, S. R., Estes, A. M., Evans, A. C., Fonov, V. S., Gerig, G., Kostopoulos, P., McKinstry, R. C., . . . Piven, J. (2017). Early brain development in infants at high risk for autism spectrum disorder. *Nature*, *542*(7641), 348–351. <https://doi.org/10.1038/nature21369>
- Hazlett, H. C., Poe, M., Gerig, G., Smith, R. G., Provenzale, J., Ross, A., Gilmore, J., & Piven, J. (2005). Magnetic resonance imaging and head circumference study of brain size in autism: Birth through age 2 years. *Archives of General Psychiatry*, *62*(12), 1366–1376. <https://doi.org/10.1001/archpsyc.62.12.1366>
- Hazlett, H. C., Poe, M. D., Gerig, G., Styner, M., Chappell, C., Smith, R. G., Vachet, C., & Piven, J. (2011). Early brain overgrowth in autism associated with an increase in cortical surface area before age 2 years. *Archives of General Psychiatry*, *68*(5), 467–476. <https://doi.org/10.1001/archgenpsychiatry.2011.39>
- Keehn, B., Shih, P., Brenner, L. A., Townsend, J., & Müller, R. A. (2013). Functional connectivity for an “island of sparing” in autism spectrum disorder: An fMRI study of visual search. *Human Brain Mapping*, *34*(10), 2524–2537. <https://doi.org/10.1002/hbm.22084>
- Landa, R. J. (2018). Efficacy of early interventions for infants and young children with, and at risk for, autism spectrum disorders. *International Review of Psychiatry*, *30*(1), 25–39. <https://doi.org/10.1080/09540261.2018.1432574>
- Li, G., Nie, J., Wang, L., Shi, F., Lin, W., Gilmore, J. H., & Shen, D. (2013). Mapping region-specific longitudinal cortical surface expansion from birth to 2 years of age. *Cerebral Cortex*, *23*(11), 2724–2733. <https://doi.org/10.1093/cercor/bhs265>

- Liu, S., Li, A., Zhu, M., Li, J., & Liu, B. (2019). Genetic influences on cortical myelination in the human brain. *Genes, Brain, and Behavior*, 18(4), e12537. <https://doi.org/10.1111/gbb.12537>
- Lord, C., & Rutter, M. (2003). *Social Communication Questionnaire (SCQ)*. Western Psychological Services.
- Lord, C., Rutter, M., DiLavore, P. C., Risi, S., Gotham, K., & Bishop, S. L. (2012). *Autism diagnostic observation schedule*, 2nd ed. (ADOS-2). Western Psychological Services.
- Lord, C., Rutter, M., & Le Couteur, A. (1994). Autism Diagnostic Interview-Revised: A revised version of a diagnostic interview for caregivers of individuals with possible pervasive developmental disorders. *Journal of Autism and Developmental Disorders*, 24(5), 659–685.
- Lyall, A. E., Shi, F., Geng, X., Woolson, S., Li, G., Wang, L., Hamer, R. M., Shen, D., & Gilmore, J. H. (2015). Dynamic development of regional cortical thickness and surface area in early childhood. *Cerebral Cortex*, 25(8), 2204–2212. <https://doi.org/10.1093/cercor/bhu027>
- Maenner, M. J., Shaw, K. A., Baio, J., Washington, A., Patrick, M., DiRienzo, M., Christensen, D. L., Wiggins, L. D., Pettygrove, S., Andrews, J. G., Lopez, M., Hudson, A., Baroud, T., Schwenk, Y., White, T., Rosenberg, C. R., Lee, L.-C., Harrington, R. A., Huston, M., ... Dietz, P. M. (2020). Prevalence of autism spectrum disorder among children aged 8 years—Autism and Developmental Disabilities Monitoring Network, 11 Sites, United States, 2016. *MMWR Surveillance Summaries*, 69(4), 1–12. <https://doi.org/10.15585/mmwr.ss6904a1>
- Mann, C., Bletsch, A., Andrews, D., Daly, E., Murphy, C., Murphy, D., & Ecker, C. (2018). The effect of age on vertex-based measures of the grey-white matter tissue contrast in autism spectrum disorder. *Molecular Autism*, 9, 49. <https://doi.org/10.1186/s13229-018-0232-6>
- McGee, A. W., Yang, Y., Fischer, Q. S., Daw, N. W., & Strittmatter, S. M. (2005). Experience-driven plasticity of visual cortex limited by myelin and Nogo receptor. *Science*, 309(5744), 2222–2226. <https://doi.org/10.1126/science.1114362>
- McKinnon, C. J., Eggebrecht, A. T., Todorov, A., Wolff, J. J., Elison, J. T., Adams, C. M., Snyder, A. Z., Estes, A. M., Zwaigenbaum, L., Botteron, K. N., McKinstry, R. C., Marrus, N., Evans, A., Hazlett, H. C., Dager, S. R., Paterson, S. J., Pandey, J., Schultz, R. T., Styner, M. A., ... Pruett, J. R., Jr. (2019). Restricted and repetitive behavior and brain functional connectivity in infants at risk for developing autism spectrum disorder. *Biological Psychiatry: Cognitive Neuroscience and Neuroimaging*, 4(1), 50–61. <https://doi.org/10.1016/j.bpsc.2018.09.008>
- Mullen, E. M. (1995). *Mullen Scales of Early Learning*. American Guidance Service.
- Nordahl, C. W., Lange, N., Li, D. D., Barnett, L. A., Lee, A., Buonocore, M. H., Buonocore, M. H., Simon, T. J., Rogers, S., Ozonoff, S., & Amaral, D. G. (2011). Brain enlargement is associated with regression in preschool-age boys with autism spectrum disorders. *Proceedings of the National Academy of Sciences of the United States of America*, 108(50), 20195–20200. <https://doi.org/10.1073/pnas.1107560108>
- Ozonoff, S., Heung, K., Byrd, R., Hansen, R., & Hertz-Picciotto, I. (2008). The onset of autism: Patterns of symptom emergence in the first years of life. *Molecular Autism*, 1(6), 320–328. <https://doi.org/10.1002/aur.53>
- Ozonoff, S., Young, G. S., Landa, R. J., Brian, J., Bryson, S., Charman, T., Chawarska, K., Macari, S. L., Messinger, D., Stone, W. L., Zwaigenbaum, L., & Iosif, A. M. (2015). Diagnostic stability in young children at risk for autism spectrum disorder: A baby siblings research consortium study. *Journal of Child Psychology and Psychiatry*, 56(9), 988–998. <https://doi.org/10.1111/jcpp.12421>
- Pierce, K., Carter, C., Weinfeld, M., Desmond, J., Hazin, R., Bjork, R., & Gallagher, N. (2011). Detecting, studying, and treating autism early: The one-year well-baby check-up approach. *Journal of Pediatrics*, 159(3), 458–465. <https://doi.org/10.1016/j.jpeds.2011.02.036>
- Pierce, K., Gazestani, V. H., Bacon, E., Barnes, C. C., Cha, D., Nalabolu, S., Lopez, L., Moore, A., Pence-Stophaeros, S., & Courchesne, E. (2019). Evaluation of the diagnostic stability of the early autism spectrum disorder phenotype in the general population starting at 12 months. *JAMA Pediatrics*, 173, 578–587. <https://doi.org/10.1001/jamapediatrics.2019.0624>
- Raichle, M. E., MacLeod, A. M., Snyder, A. Z., Powers, W. J., Gusnard, D. A., & Shulman, G. L. (2001). A default mode of brain function. *Proceedings of the National Academy of Sciences of the United States of America*, 98(2), 676–682. <https://doi.org/10.1073/pnas.98.2.676>
- Rosen, M. L., Amso, D., & McLaughlin, K. A. (2019). The role of the visual association cortex in scaffolding prefrontal cortex development: A novel mechanism linking socioeconomic status and executive function. *Developmental Cognitive Neuroscience*, 39, 100699. <https://doi.org/10.1016/j.dcn.2019.100699>
- Rowley, C. D., Sehmbi, M., Bazin, P. L., Tardif, C. L., Minuzzi, L., Frey, B. N., & Bock, N. A. (2017). Age-related mapping of intracortical myelin from late adolescence to middle adulthood using T(1)-weighted MRI. *Human Brain Mapping*, 38(7), 3691–3703. <https://doi.org/10.1002/hbm.23624>
- Sacrey, L. R., Zwaigenbaum, L., Bryson, S., Brian, J., Smith, I. M., Roberts, W., Roberts, W., Szatmari, P., Vaillancourt, T., Roncadin, C., & Garon, N. (2018). Parent and clinician agreement regarding early behavioral signs in 12- and 18-month-old infants at-risk of autism spectrum disorder. *Autism Research*, 11(3), 539–547. <https://doi.org/10.1002/aur.1920>
- Shafee, R., Buckner, R. L., & Fischl, B. (2015). Gray matter myelination of 1555 human brains using partial volume corrected MRI images. *Neuroimage*, 105, 473–485. <https://doi.org/10.1016/j.neuroimage.2014.10.054>
- Shaw, P., Kabani, N. J., Lerch, J. P., Eckstrand, K., Lenroot, R., Gogtay, N., Greenstein, D., Clasen, L., Evans, A., Rapoport, J. L., Giedd, J. N., & Wise, S. P. (2008). Neurodevelopmental trajectories of the human cerebral cortex. *Journal of Neuroscience*, 28(14), 3586–3594. <https://doi.org/10.1523/jneurosci.5309-07.2008>
- Solso, S., Xu, R., Proudfoot, J., Hagler, D. J., Jr., Campbell, K., Venkatraman, V., Barnes, C. C., Ahrens-Barbeau, C., Pierce, K., Dale, A., Eyer, L., & Courchesne, E. (2016). Diffusion tensor imaging provides evidence of possible axonal overconnectivity in frontal lobes in autism spectrum disorder toddlers. *Biological Psychiatry*, 79(8), 676–684. <https://doi.org/10.1016/j.biopsych.2015.06.029>
- Sowell, E. R., Thompson, P. M., Leonard, C. M., Welcome, S. E., Kan, E., & Toga, A. W. (2004). Longitudinal mapping of cortical thickness and brain growth in normal children. *Journal of Neuroscience*, 24(38), 8223–8231. <https://doi.org/10.1523/jneurosci.1798-04.2004>
- Sparrow, S. S., Cicchetti, D. V., & Balla, D. A. (2005). *Vineland Adaptive Behavior Scales, Second Edition*. American Guidance Service.
- Spear, L. P. (2013). Adolescent neurodevelopment. *Journal of Adolescent Health*, 52(2), S7–S13. <https://doi.org/10.1016/j.jadohealth.2012.05.006>
- Sydnor, V. J., Larsen, B., Bassett, D. S., Alexander-Bloch, A., Fair, D. A., Liston, C., Mackey, A. P., Milham, M. P., Pines, A., Roalf, D.

- R., Seidlitz, J., Xu, T., Raznahan, A., & Satterthwaite, T. D. (2021). Neurodevelopment of the association cortices: Patterns, mechanisms, and implications for psychopathology. *Neuron*, *109*, 2820–2846. <https://doi.org/10.1016/j.neuron.2021.06.016>
- Tomassy, G. S., Berger, D. R., Chen, H. H., Kasthuri, N., Hayworth, K. J., Vercelli, A., Seung, H. S., Lichtman, J. W., & Arlotta, P. (2014). Distinct profiles of myelin distribution along single axons of pyramidal neurons in the neocortex. *Science*, *344*(6181), 319–324. <https://doi.org/10.1126/science.1249766>
- Travers, B. G., Adluru, N., Ennis, C., do, T. P. M., Destiche, D., Doran, S., Bigler, E. D., Lange, N., Lainhart, J. E., & Alexander, A. L. (2012). Diffusion tensor imaging in autism spectrum disorder: A review. *Autism Research*, *5*(5), 289–313. <https://doi.org/10.1002/aur.1243>
- Turesky, T. K., Vanderauwera, J., & Gaab, N. (2021). Imaging the rapidly developing brain: Current challenges for MRI studies in the first five years of life. *Developmental Cognitive Neuroscience*, *47*, 100893. <https://doi.org/10.1016/j.dcn.2020.100893>
- Wang, Q., Li, H. Y., Li, Y. D., Lv, Y. T., Ma, H. B., Xiang, A. F., Jia, X. Z., & Liu, D. Q. (2021). Resting-state abnormalities in functional connectivity of the default mode network in autism spectrum disorder: A meta-analysis. *Brain Imaging and Behavior*, *15*(5), 2583–2592. <https://doi.org/10.1007/s11682-021-00460-5>
- Weitzman, C., & Wegner, L. (2015). Promoting optimal development: Screening for behavioral and emotional problems. *Pediatrics*, *135*(2), 384–395. <https://doi.org/10.1542/peds.2014-3716>
- White, N., Roddey, C., Shankaranarayanan, A., Han, E., Rettmann, D., Santos, J., Kuperman, J., & Dale, A. (2010). PROMO: Real-time prospective motion correction in MRI using image-based tracking. *Magnetic Resonance in Medicine*, *63*(1), 91–105. <https://doi.org/10.1002/mrm.22176>
- Wierenga, L. M., Langen, M., Oranje, B., & Durston, S. (2014). Unique developmental trajectories of cortical thickness and surface area. *Neuroimage*, *87*, 120–126. <https://doi.org/10.1016/j.neuroimage.2013.11.010>
- Wolff, J. J., Gu, H., Gerig, G., Elison, J. T., Styner, M., Gouttard, S., Botteron, K. N., Dager, S. R., Dawson, G., Estes, A. M., Evans, A. C., Hazlett, H. C., Kostopoulos, P., McKinstry, R. C., Paterson, S. J., Schultz, R. T., Zwaigenbaum, L., & Piven, J. (2012). Differences in white matter fiber tract development present from 6 to 24 months in infants with autism. *American Journal of Psychiatry*, *169*(6), 589–600. <https://doi.org/10.1176/appi.ajp.2011.11091447>
- Xiao, Z., Qiu, T., Ke, X., Xiao, X., Xiao, T., Liang, F., Zou, B., Huang, H., Fang, H., Chu, K., Zhang, J., & Liu, Y. (2014). Autism spectrum disorder as early neurodevelopmental disorder: Evidence from the brain imaging abnormalities in 2–3 years old toddlers. *Journal of Autism and Developmental Disorders*, *44*(7), 1633–1640. <https://doi.org/10.1007/s10803-014-2033-x>
- Yerys, B. E., Gordon, E. M., Abrams, D. N., Satterthwaite, T. D., Weinblatt, R., Jankowski, K. F., Strang, J., Kenworthy, L., Gaillard, W. D., & Vaidya, C. J. (2015). Default mode network segregation and social deficits in autism spectrum disorder: Evidence from non-medicated children. *Neuroimage Clinical*, *9*, 223–232. <https://doi.org/10.1016/j.nicl.2015.07.018>

How to cite this article: Chen, B., Linke, A., Olson, L., Kohli, J., Kinnear, M., Sereno, M., Müller, R.-A., Carper, R., & Fishman, I. (2022). Cortical myelination in toddlers and preschoolers with autism spectrum disorder. *Developmental Neurobiology*, *82*, 261–274. <https://doi.org/10.1002/dneu.22874>